

Rapid Calcification of Myocardium as Sequela from Severe Sepsis

Andreas S. Kunz^{1,*}, Matthias Beissert¹, Thorsten Klink¹

1. University Hospital Wurzburg, Department of Diagnostic and interventional Radiology

The Case

The reported case shall highlight severe sepsis as possible cause of myocardial calcification, as well as the highly dynamic development thereof within a time span of merely 10 weeks. A 60-year-old male patient had been admitted to hospital for palliative therapy of progressive multiple myeloma, which lately had transformed into plasma cell leukemia. After commencing his third therapy cycle with Elotuzumab, the patient suffered from a pneumogenic sepsis due to staphylococcus infection that required mechanical ventilation for 7 days. Antimicrobial therapy followed antimicrobial susceptibility testing and included Tazobactam, Piperacillin, and Fosfomycin. During his hospital stay, computed tomography images of the chest were acquired initially, i.e. at onset of pneumogenic sepsis (Fig 1.: left panel), as well as after 10 weeks (Fig. 1: right panel) to follow-up pneumonia consolidations in both upper lung lobes. Surprisingly, non-contrast enhanced follow-up CT images revealed newly developed calcifications within the outer myocardial layers of the left ventricle.

Only very few reports exist describing myocardial calcification as sequela from severe sepsis. Explanations attribute alterations of myocardial microcirculation to cause subsequent tissue necrosis during septic shock and capillary leak and relative capillary stasis.¹ Resulting interstitial and intracellular edema, and consecutive mitochondrial destruction and cellular necrosis.² In other cases, myocardial calcifications have been described as complication resulting from myocarditis.³

In general, myocardial calcifications are associated with myocyte necrosis due to severe infection or inflammation, and can lead to restrictive cardiomyopathy. Differential diagnoses include calcifications of the inner myocardial layers, which can be detected after myocardial infarction, and pericardial calcifications that indicate constrictive pericarditis.

References:

1. Hinshaw LB (1996) Sepsis/septic shock: participation of the microcirculation. Crit Care Med 24:1072–1078
2. Hersh M (1990) Histologic and ultrastructural changes in non-pulmonary organs during early hemodynamic sepsis. Surgery 107:397–410
3. Wang KY (2017) Calcifying giant cell cardiomyopathy: a possible new entity: Images in Cardiovascular Pathology. Cardiovasc Pathol. 2017 Mar 12;28:68-70 [Epub ahead of print]

Corresponding author: Andreas S. Kunz, University Hospital Wurzburg, Department of Diagnostic and interventional Radiology

Citation: Andreas S. Kunz, Matthias Beissert, Thorsten Klink (2017) Rapid Calcification of Myocardium as Sequela from Severe Sepsis. Journal of Clinical Images and Case reports - 1(1):1-2. <https://doi.org/10.14302/issn.2641-5518.jcci-17-1509>

Editor: Anil TOMBAK, Mersin University Faculty of Medicine

Keywords: Myocardial Calcification

Received: Mar 30, 2017

Accepted: April 26, 2017

Published: Aug 08, 2017;

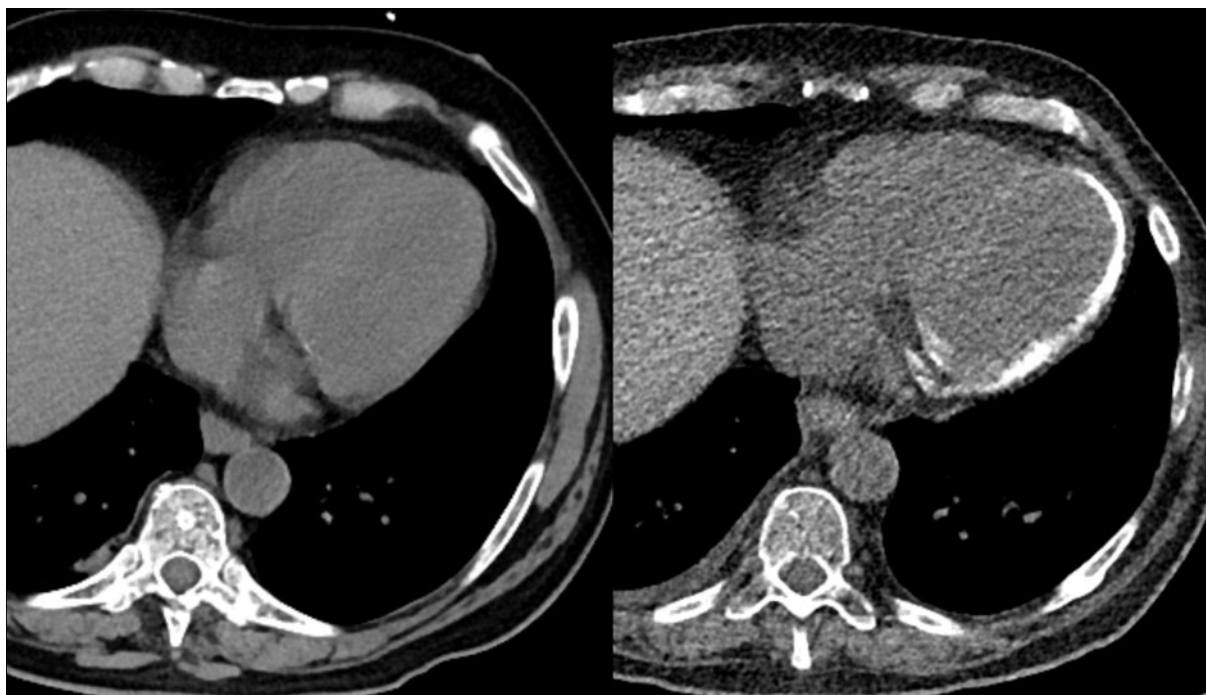


Figure 1: Non-contrast enhanced CT scans of the chest initially during onset of pneumogenic sepsis (right) and after 10 weeks (left) show rapid development of non-preexisting, extensive myocardial calcifications.